

Research Article

The Role of AMP-activated Protein Kinase (AMPK) in Pathogenesis of Polycystic Ovary Syndrome



Noura Hassan Khamis¹, Randa Ahmed Ibrahim¹, Soha Abd-elkawy Abd-elwahab¹, Rehab Ahmed Rifaai¹ and Nashwa Fathy Gamal El-Tahawy¹

¹Department of Histology and Cell Biology, Minia University, Faculty of medicine, Egypt.

DOI: [10.21608/MJMR.2023.211602.1399](https://doi.org/10.21608/MJMR.2023.211602.1399)

Abstract

Background: Polycystic ovary syndrome (PCOS) is one of the most common endocrine disorder affecting female reproductive life. PCOS is multifaceted disorder and to date there is no defined cause or therapy. Several causes were implied as being contributing factors in the mechanism of this disease including hyperandrogenism, insulin resistance, obesity and chronic inflammation. **Aims:** In this study insulin resistance is considered as one of the main pathogenesis in letrozole induced animal model of polycystic ovary, so treatment of insulin resistance by different drug regimen will be helpful in the treatment of PCOS and its complications. **Methods:** 20 female albino rats were divided into two groups 10 rats each; the control group (received the vehicle) and the PCO group received letrozole (1 mg/kg/day) dissolved in 1% carboxymethyl cellulose orally for five weeks. Ovaries and serum were harvested and studied biochemically, histologically and immunohistochemically. **Results:** Biochemical analysis showed a significant increase in serum testosterone and insulin hormones and HOMA-IR and in tissues A type fatty acid binding protein (A-FABP). **Conclusion:** AMPK upregulation in PCO group could implicate it in pathogenesis of PCOS.

Keywords: Insulin resistance, A-FABP, HOMA-IR

Introduction

Polycystic ovary syndrome (PCOS) is an endocrine-gynecological disorder affecting many women in childbearing period. Although some factors contributing in the PCOS pathogenesis has been discovered, the exact etiology and pathophysiology are not well known as yet ^[1]. Many studies suggest the role of different factors as hyperandrogenism (HA), insulin resistance (IR), environmental, genetic, and epigenetic factors. PCOS can predispose to many complications like diabetes mellitus type 2, cardiovascular diseases and metabolic syndrome ^[2].

Several studies have investigated the prevalence of PCOS, however, there are discrepancies in

their results, this may be due to the use of different definitions of the disease and its phenotypes, differences among study cohorts, ethnicities, and types of recruitment and sampling. The reported overall prevalence of PCOS according to diagnostic criteria of the national institute of health (NIH), Rotterdam criteria and the androgen excess- PCOS (AE-PCOS) Society is 6%, 10% and 10% respectively ^[3].

Aromatase is the enzyme that can convert androgen to estrogen in the cycle of steroid hormone synthesis. Letrozole is an aromatase inhibitor which block the conversion of testosterone to estrogen, so can lead to a state of

hyperandrogenism, thus it has been widely used to develop models for polycystic ovary^[4].

AMP-activated protein kinase (AMPK) is a major regulator of energy balance within the cell. Activation of AMPK lead to inhibition of the anabolic pathways and activation of the ATP production pathways via fatty acid oxidation and muscle glucose transport^[5]

Adipocyte fatty acid-binding protein (A-FABP) that is also known as FABP4, is a fatty acid chaperone. It controls lipid homeostasis and it also has a role in inflammation. Circulating levels of A-FABP are mainly associated with metabolic syndrome^[6].

Animals:

Twenty female albino rats (average age 3-4 weeks, average weight 70-80 grams) were included in the study. Animals were acclimatized for 2 weeks before starting the experiment. They were kept in clean cages with access to water and standard laboratory diets and were exposed to 12 hours dark and 12 hours light cycle. Laboratory temperature was kept at range from 24-30°C. This study followed the guidelines approved by Minia University institutional Ethics Committee for use of laboratory animals it had approval number (44:6/2021).

Chemicals:

- * Letrozole (Femara^c- Novartis pharmaceutical company- Egypt) in the form of tablets 2.5 mg.
- * Anti-AMPK antibody (A7339, 1:200; Abclonal, USA).
- *A-FABP (NOVUS BIOLOGICALS, Catalog number: NBP2-82484).

Induction of polycystic ovary:

Regular vaginal smear of rats for two weeks to make sure of regularity of estrous cycle was performed daily using the pipette smear technique^[7]. Rats with regular estrous cycle for at least two consecutive cycles were involved in the study. Ten rats received letrozole (1mg/kg) dissolved in 1% carboxymethyl cellulose orally for 5 weeks, modified from^[8]. Vaginal smear was done during the last two weeks experiment

to assure that animals have persistent di-estrous stage of estrous cycle, so that become models for PCO.

Experimental design:

Animals were randomly into two groups, ten rat per each and treated for 5 weeks as follow:

- 1- Control group:** Received the vehicle, 1% carboxymethyl cellulose orally
- 2- Polycystic ovary group (PCO-group):** Received letrozole orally.

Blood and tissue collection:

At the end of the experiment, animals were fasted overnight and anaesthetized using halothane inhalation. For fixation, intracardiac perfusion using 10% buffered formalin was done. Fasting blood glucose for both groups were assessed immediately. Heparinized tubes were used for the rest of the collected blood, centrifuged (3000×g for 10 min at 4°C) in order to obtain sera which were kept at -20°C. ovaries were harvested, cleaned and one ovary from each animal was used for protein extraction and the other was fixed in 10% buffered formalin for preparation for paraffin technique.

Biochemical study:

➤ Hormonal study:

Sera were used for estimation testosterone hormone (CUSABIO Reagent Kit, USA, Catalog Number: CSB-E05100r), and insulin hormone (Elbasience Biotechnology Inc. Catalog Number: E-EL-R2466) using ELISA kits according to the manufacturer instructions.

➤ Study of insulin resistance:

The homeostasis model assessment-estimated insulin resistance (HOMA-IR) has been used to calculate the insulin resistance. It was calculated by multiplying fasting plasma glucose (FPG) by fasting plasma insulin (FPI) then dividing by a constant (22.5) i.e. $HOMA-IR = (FPG \times FPI) / 22.5$ ^[7].

➤ Measurement of Adipocyte Fatty Acid Binding Protein (A-FABP):

Tissue samples of the ovary were ground with liquid nitrogen using a mortar. The ground tissues were then treated with 4.5 ml of phosphate buffer saline. The mixture was then

homogenized on ice by an Ultra-Turrax homogenizer for about 15 minutes. Homogenates were used for detection of (A-FABP) using ELIZA kits.

Histological assessment

Ovarian tissue samples were fixed using 10% buffered formalin then were processed in order to obtain paraffin blocks. Serial sections of about (5–7 µm) were then stained using hematoxylin and eosin stain and Masson's trichrome stain.

Immunohistochemical assessment:

For immunohistochemical staining avidin- biotin-peroxidase technique was used for anti-AMPK antibody. Paraffin sections were first deparaffinized in xylene, rehydrated then rinsed in tape water, and then embedded in hydrogen peroxide 3% (H₂O₂) for ten minutes so that inhibit the endogenous activity of peroxidase enzyme. For antigen retrieval, sections were pre-treated in 0.01 µl sodium citrate buffer (pH 6.0) in a microwave oven for about ten minutes then followed by cooling for about twenty minutes. Incubation of the sections with the corresponding primary antibodies then incubation with goat anti rabbit biotinylated secondary antibody was done to detect them. Sections then were counterstained using hematoxylin stain, then dehydrated, cleared, and eventually were mounted on the glass slides. Visualization of the tissues was done by using horseradish peroxidase-avidin-biotin complex then 3,3'- diaminobenzidine in hydrogen peroxide. The reaction appeared as brownish cytoplasmic granules.

Image capture:

Slides were viewed and photographed with a high-resolution color digital camera and mounted on a BX51 light microscope (Olympus, Japan), the camera was connected to a computer having LC micro software application.

Statistical analysis:

Quantitative data analysis was performed using Graph Pad Prism (version 9.01 for Windows, Graph Pad Software-San Diego-California-USA). Results were expressed as Mean ± SEM. For the detection of significant differences between the

two groups One-way analysis of variance (ANOVA) test was used, then followed by Tukey-Kramer post hoc test for comparison between groups. The results were statistically significant if the p values were less than 0.05.

Results

Biochemical results:

Serum testosterone hormone, insulin hormone and HOMA-IR and tissue level of A-FABP showed a significant (P value < 0.0001) upregulation in in the PCO group in comparison to the control group (Table 1,2,3&4).

Histological results:

Histological assessment:

***Hematoxylin and Eosin (H&E) staining for structural changes:**

➤ **Control group:**

Ovarian sections appeared normally consisting germinal epithelium surrounding an outer cortex and inner medulla. The medulla appeared with vascularized connective tissue and interstitial cells. The cortex had ovarian follicles at various stages of growth and maturation, including Primordial follicles, uni-laminar and multilaminar primary follicles, Secondary follicles and mature graafian follicles (Fig. 1A1- A2).

➤ **PCO group:**

Showed the medulla with many congested blood vessels and the cortex had numerous large cystic follicles of variable sizes and shapes. Each cyst had an acidophilic material in its lumen with no oocyte. Cysts were separated by highly cellular interstitial stromal cells. Multiple atretic follicles were observed with absence of corpus luteum and growing follicles (Fig. 1B1-B2).

Masson trichrome staining for assessing collagen:

There was a delicate amount of collagen fibers in the control group (Fig. 2 A1-A2). However, a significant increase in the amount of collagen fibers was detected in the PCO group (Fig. 2 B1-B2).

*** Immunohistochemical results for assessing marker expression:**

AMPK immune-expression:

Negative expression of most cells lining the follicles of the control group and only few cells had positive cytoplasmic expression (Fig.3A1-A2). However, in the PCO group there was

extensive positive immune-expression of both granulosa cells and theca cells forming the cystic follicles (Fig. 3 B1-B2).

**Table (1): Serum testosterone hormone level in the studied groups. P value is significant < 0.05.
C versus control group.**

Group	Mean ±SEM	p-value
Control group	1.023 ± 0.02	
PCO group	2.87 ± 0.05	<0.0001* ^C

**Table (2): Mean Insulin hormone level in the studied groups. P-value is significant < 0.05.
C versus control group.**

Group	Mean ± SEM	p-value
Control group	0.54 ± 0.007	
PCO group	1.22 ± 0.007	<0.0001* ^C

**Table (3): Mean HOMA-IR level in the studied groups. P-value is significant < 0.05.
C versus control group.**

Group	Mean ± SEM	p-value
Control group	1.45 ± 0.02	
PCO group	3.87 ± 0.02	<0.0001* ^C

Table (4): Mean tissue level of A-FABP in different groups. P-value is significant < 0.05.^C versus control group.

Group	Mean ±SEM	p-value
Control group	1.11 ± 0.03	
PCO group	3.34 ± 0.07	<0.0001* ^C

Figure legends:

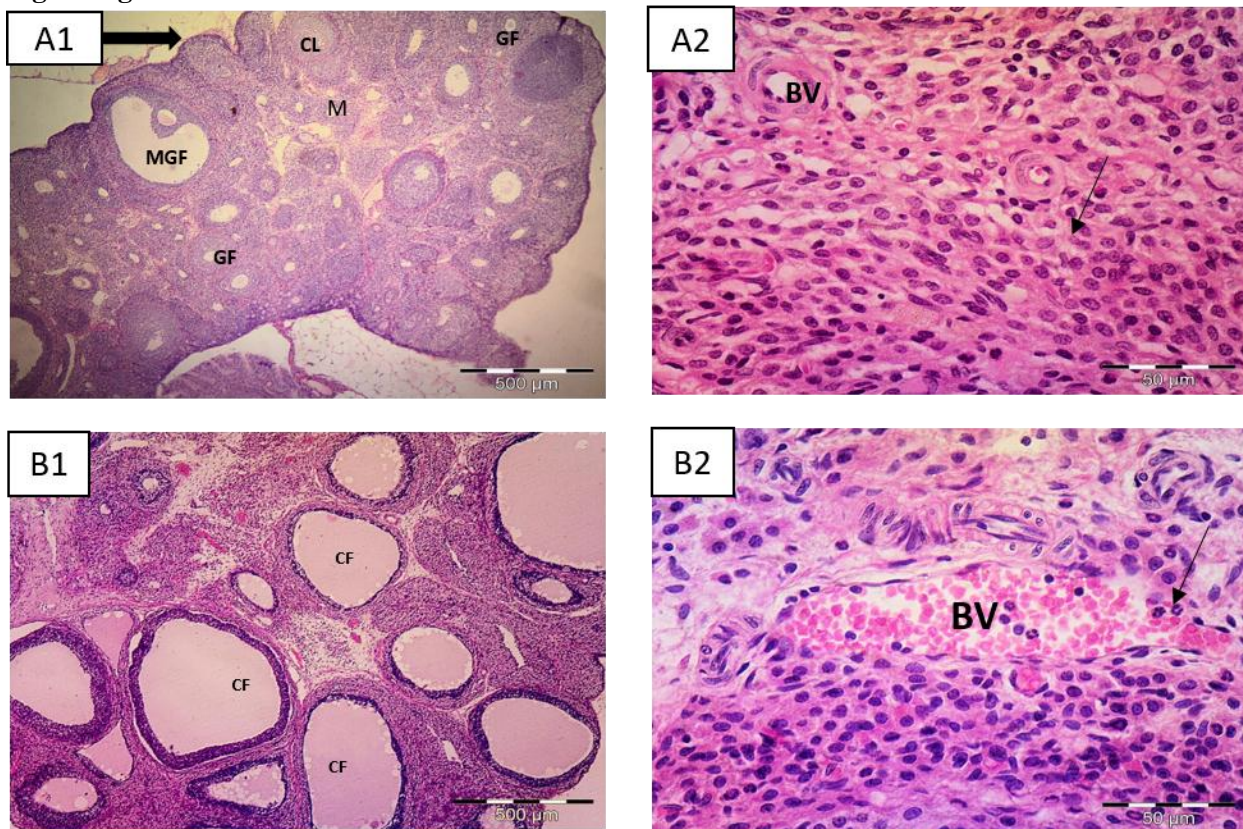


Fig. (1): Representative photomicrographs of rat ovarian tissues sections of the studied groups: Control group (A1, A2) showing normal histological ovarian appearance; outer cortex (C) surrounded by germinal epithelium (thick arrow) and inner medulla (M). The cortex contains mature graafian follicle (MGF), corpus luteum (CL) and other growing follicles (GF). A2) Higher magnification showing the medulla with vascularized (BV) connective tissue and interstitial cells (arrow). PCO group (B1-B2) showing numerous large cystic follicles (CF) with absence of oocytes and acidophilic material in lumen occupying the cortex with absence of corpus luteum and growing follicles. B2) Higher magnification showing congested medullary blood vessels (BV) and hypercellular infiltrate (arrow). H&E (A1,B1)×10 & (A2,B2) X 40

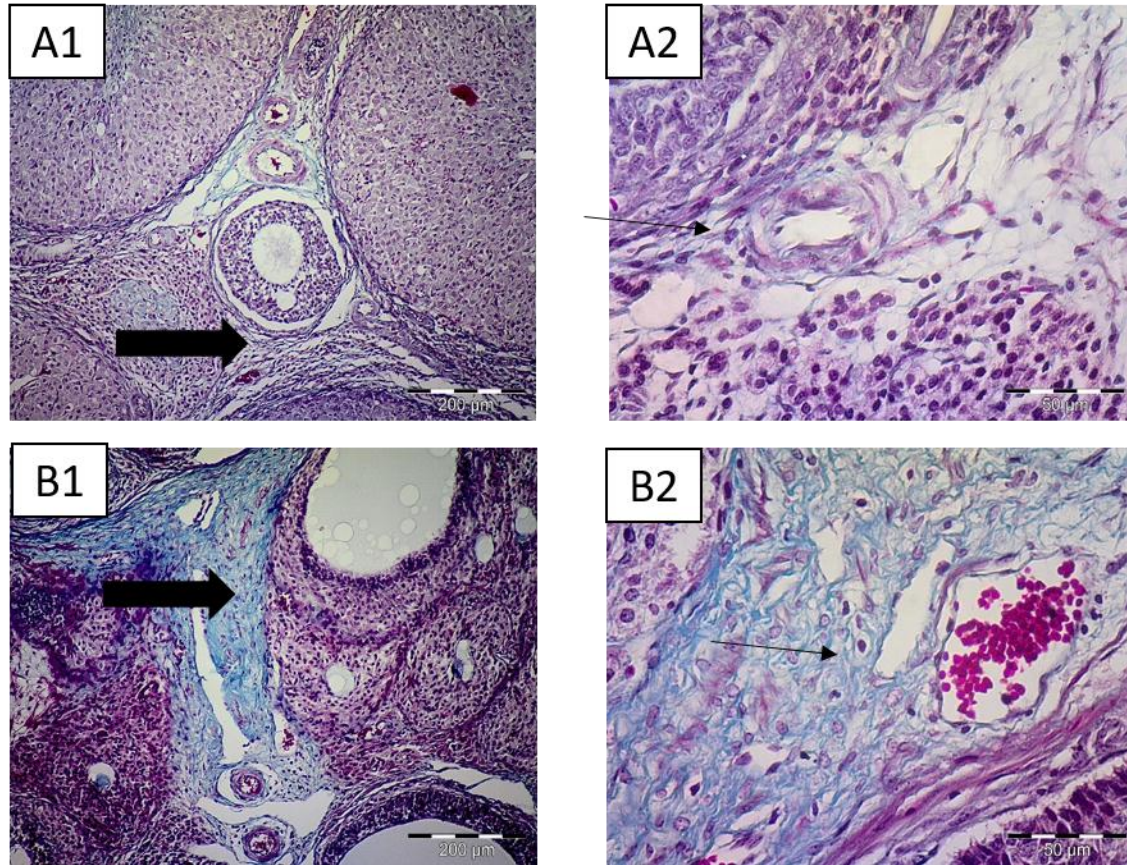


Fig. (2): Representative photomicrographs of rat ovarian tissues stained with masson trichrome stain in different group:

The Control group (A1-A2) showing delicate amount of collagen fibers between the follicles (thick arrow) and around blood vessels (thin arrows).

The PCO group (B1-B2) showing increased amount of collagen fibers between the follicles (thick arrows) and around blood vessels (thin arrow).

Masson trichrome stain (A1, B1) x10 & (A2,B2)x 40

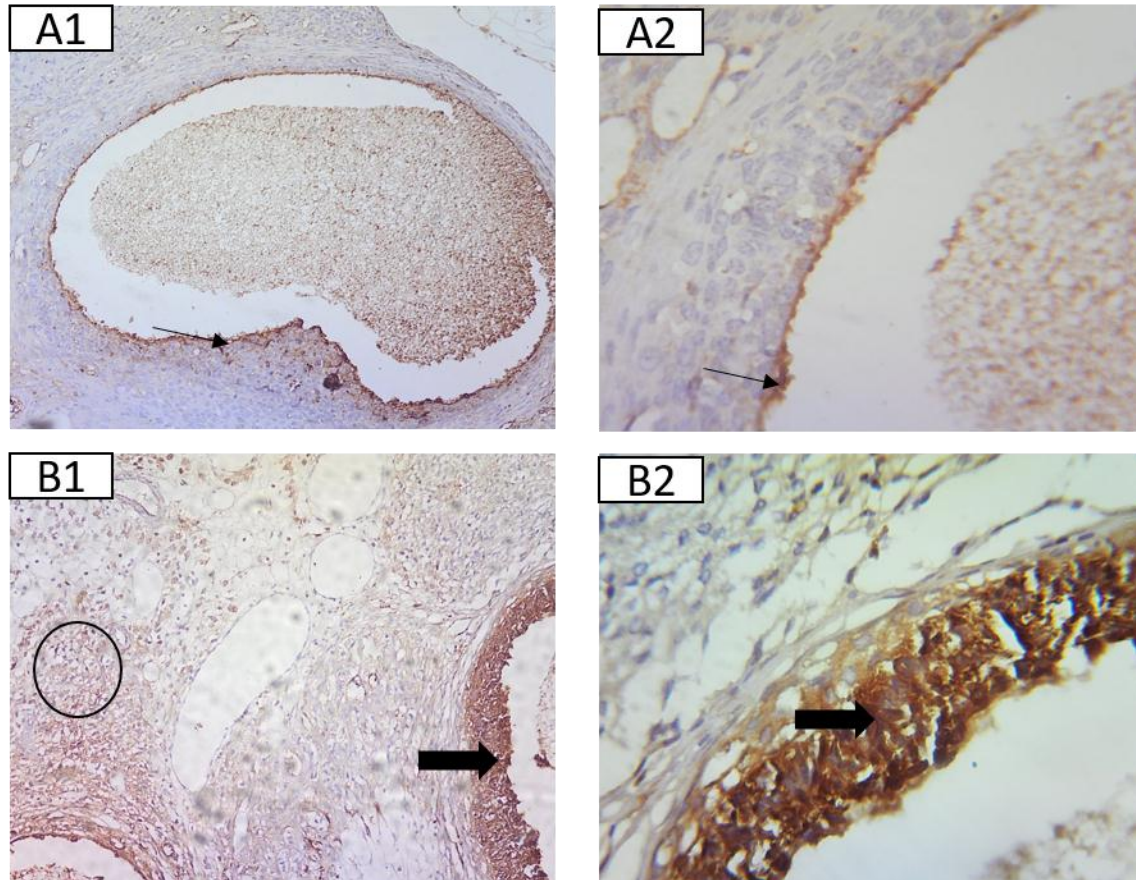


Fig. (3): Representative photomicrographs of rat ovarian tissues immunostained for AMPK from **the control group** (A1-A2) showing negative expression of most cells and only few granulosa cells are immunopositive stained (thin arrows).

The PCO group (B1-B2) showing extensive immune-expression in the granulosa cells of the cystic follicles (thick arrows) and in the stromal cells (circle).

AMPK immunohistochemistry, counterstained with H (A1, B1) x10 & (A2, B2) x 40.

Discussion

Polycystic ovarian syndrome (PCOS) is one of the most common factors causing infertility in women in childbearing period. However, up to date, there is no definite therapeutic strategy has been estimated for this complex disease^[9].

In this study, letrozole was used to induce polycystic ovary model in female rats. Letrozole is an aromatase inhibitor that can increase the testosterone hormone levels by blocking the conversion of testosterone to estrogen, and lead to

a state of hyperandrogenism and polycystic changes in the ovary, so that letrozole has been used to develop models for PCOS^[10]

The PCO model in this study has characteristics of polycystic ovary in the form of morphological and hormonal changes. Hormonal changes included significant high serum testosterone level, serum insulin level and HOMA-IR (an indicator of insulin resistance). This is the same results reported by^[11] who used letrozole to induce PCO model.

Hyperandrogenism resulted from inhibition of aromatase enzyme, this inhibition block conversion of testosterone to estrogen. This was worsened by hyperinsulism as insulin would result in more hyperandrogenism either directly as insulin has been reported to act as a co-gonadotropin so that stimulate biosynthesis of androgen in the ovary as it can activate cytochrome P450c17 expression in the theca cells^[12]. Indirectly insulin can decrease the level of sex hormone binding globulin (SHBG) so can increase the free testosterone in the blood, resulting in high androgenic activity. Several studies reported that insulin can reduce SHBG release from the liver^[13].

The hyperinsulinemia resulted from IR induced by increase in androgen level in letrozole treated groups^[14]. Furthermore, chronic low-grade inflammation as an essential factor in the pathogenesis of PCOS was suggested to be another cause of IR. The pro-inflammatory cytokine tumor necrosis factor- alpha (TNF-alpha) is a known mediator of IR^[15].

In the present study, tissue content of A-FABP was significantly high in the PCO group. A-FABP mRNA expression was higher in granulosa cells in patients ovaries with PCOS than in the controls^[16]. A-FABP induced insulin resistance via degradation of peroxisome proliferator activated receptors γ (PPAR γ) in adipose tissue and subsequently decreased expression of insulin-sensitizing adiponectin^[17].

Histological results revealed that the PCO group showed ovarian cortical changes with numerous large cystic follicles of variable sizes and shapes and medullary vascular congestion. Cysts exhibited absence of oocytes with acidophilic material in the lumen in line with^[11] and^[18]. Presence of many atretic follicles and absence of corpus luteum detected in this study were in accordance with previous study^[19].

By using Masson trichrome stain there was high level in the amount of collagen fibers in the PCO group in comparison to the control group. This finding was in accordance with^[20]. Increase

collagen and fibrotic changes could be attributed to inflammation with subsequent increase in reactive oxygen species and proinflammatory cytokines (TNF- α and nuclear transcription factor- Kappa-B) with decrease anti-inflammatory cytokines^[21].

AMPK local upregulation in PCO group could contribute to pathogenesis of this disorder. AMPK can act as an energy sensor monitoring cell energy levels. It is activated by energy-depleting factors such as glucose deprivation, oxidative stress and hypoxia. These factors can result in increase in the intracellular AMP: ATP ratio. Activated AMPK decrease the ATP consuming metabolic pathways and stimulate the energy generating pathways by phosphorylating the primary targets involved in energy metabolism, so that it maintain the energy balance inside cells^[22].

PCO animal model showed IR that affect the ovary by deriving oocytes from glucose with subsequent activation of AMPK. In accordance with these results, a study found that depletion of glucose promoted the phosphorylation of AMPK with a significant increase of p53, so that stimulating p53-dependent apoptosis that result in apoptosis in granulosa cell layer observed in this study^[23].

In conclusion, insulin resistance as one of the main contributing factors in the pathogenesis of PCOS can result in glucose deprivation in the ovarian tissue that result in activation of AMPK. Treatment of insulin resistance in patients with PCOS can be helpful in the treatment of PCOS and its comorbidities.

References

1. Sadeghi, H.M., et al., Polycystic Ovary Syndrome: A Comprehensive Review of Pathogenesis, Management, and Drug Repurposing. *International Journal of Molecular Sciences*, 2022. 23(2): p. 583.
2. Glueck, C.J. and N. Goldenberg, Characteristics of obesity in polycystic ovary syndrome: etiology, treatment, and genetics. *Metabolism*, 2019. 92: p. 108-120.

3. Bozdag, G., et al., The prevalence and phenotypic features of polycystic ovary syndrome: a systematic review and meta-analysis. *Human reproduction*, 2016. 31(12): p. 2841-2855.
4. Chaudhari, N.K., Neuro-Endocrine Modulations in Polycystic Ovarian Syndrome Rat Model. 2018, Maharaja Sayajirao University of Baroda (India).
5. Mičić, B., et al., AMPK Activation Is Important for the Preservation of Insulin Sensitivity in Visceral, but Not in Subcutaneous Adipose Tissue of Postnatally Overfed Rat Model of Polycystic Ovary Syndrome. *International Journal of Molecular Sciences*, 2022. 23(16): p. 8942.
6. Li, H.-L., et al., A-FABP in Metabolic Diseases and the Therapeutic Implications: An Update. *International journal of molecular sciences*, 2021. 22(17): p. 9386.
7. Attia, G.M., R.A. Elmansy, and M.H. ElSayed, Metformin decreases the expression of VEGF-A and CTGF-1 and improves histological, ultrastructural and hormonal changes in adult rat polycystic ovary. *Folia Biologica (Kraków)*, 2019. 67(1): p. 25-43.
8. Kamal, D.A.M., et al., Kelulut Honey Ameliorates Oestrus Cycle, Hormonal Profiles, and Oxidative Stress in Letrozole-Induced Polycystic Ovary Syndrome Rats. *Antioxidants*, 2022. 11(10): p. 1879.
9. Peng, G., et al., The effects of first-line pharmacological treatments for reproductive outcomes in infertile women with PCOS: a systematic review and network meta-analysis. *Reproductive Biology and Endocrinology*, 2023. 21(1): p. 1-12.
10. Yang, H., et al., Therapeutic effect of Ecklonia cava extract in letrozole-induced polycystic ovary syndrome rats. *Frontiers in pharmacology*, 2018. 9: p. 1325.
11. Atef, M.M., et al., Therapeutic potential of sodium selenite in letrozole induced polycystic ovary syndrome rat model: Targeting mitochondrial approach (selenium in PCOS). *Archives of biochemistry and biophysics*, 2019. 671: p. 245-254.
12. Rosenfield, R.L. and D.A. Ehrmann, The pathogenesis of polycystic ovary syndrome (PCOS): the hypothesis of PCOS as functional ovarian hyperandrogenism revisited. *Endocrine reviews*, 2016. 37(5): p. 467-520.
13. Qu, X. and R. Donnelly, Sex hormone-binding globulin (SHBG) as an early biomarker and therapeutic target in polycystic ovary syndrome. *International journal of molecular sciences*, 2020. 21(21): p. 8191.
14. Wang, J., et al., Hyperandrogenemia and insulin resistance: The chief culprit of polycystic ovary syndrome. *Life sciences*, 2019. 236: p. 116940.
15. González, F., Inflammation in polycystic ovary syndrome: underpinning of insulin resistance and ovarian dysfunction. *Steroids*, 2012. 77(4): p. 300-305.
16. Hu, W. and J. Qiao, Expression and regulation of adipocyte fatty acid binding protein in granulosa cells and its relation with clinical characteristics of polycystic ovary syndrome. *Endocrine*, 2011. 40(2): p. 196-202.
17. Kralisch, S., et al., Circulating adipocyte fatty acid-binding protein induces insulin resistance in mice in vivo. *Obesity*, 2015. 23(5): p. 1007-1013.
18. Rajan, R.K. and B. Balaji, Soy isoflavones exert beneficial effects on letrozole-induced rat polycystic ovary syndrome (PCOS) model through anti-androgenic mechanism. *Pharmaceutical biology*, 2017. 55(1): p. 242-251.
19. ELHAM, M.N., et al., Effect of Crocin on Letrozole-Induced Polycystic Ovarian Syndrome. *The Medical Journal of Cairo University*, 2019. 87(December): p. 5237-5243.
20. Abd El-Galil, M., Mona and F. Mohammed, Shaymaa, The Possible Effect Of Flaxseed Extract On Letrozole-Induced Polycystic Ovary Rat Model: Correlative Histological And Functional Study. *Al-Azhar Medical Journal*, 2021. 50(4): p. 3051-3096.
21. Sorour, A., Hekmat, F. Abdel Aal, and M. Abd-Elgalil, Ovarian cytoarchitectural

- changes following fennel ingestion in senile diabetic albino rat. Egyptian journal of histology, 2017. 40(4): p. 427-442.
22. Stahmann, N., et al., Activation of AMP-activated protein kinase by vascular endothelial growth factor mediates endothelial angiogenesis independently of nitric-oxide synthase. Journal of Biological Chemistry, 2010. 285(14): p. 10638-10652.
 23. Okoshi, R., et al., Activation of AMP-activated protein kinase induces p53-dependent apoptotic cell death in response to energetic stress. Journal of biological chemistry, 2008. 283(7): p. 3979-3987.