

*Research Article***Perineal trauma & Anal Sphincter Injuries:
Treatment Outcomes in Minia University Emergency Unit****Ahmad N. Mohamed¹, Tohamy A. Tohamy¹, Doaa A. Saad Kamel¹,
and Mohamed Kh. Allah¹**¹ General Surgery Department, Faculty of Medicine, Minia University**Abstract**

Background: Fecal incontinence is a very distressing problem that affects quality of life and has social aspects. we aimed at reaching standardized and systematic lines of treatment to get the best results after perineal trauma and minimize the incidence of fecal incontinence. **Methods:** all patients we encountered that have acute perineal injury regardless of severity of the injury, mode of trauma , associated injuries, presence of anorectal injury. This study has been conducted in El-Minia university hospital, emergency unit including 32 patients in the period between March 2021 and December 2021. The main operative treatment applied in the study was immediate lry repair in the emergency setting using overlapping technique, with or without bowel diversion according to the evaluation of each individual case. The post-operative continence in the studied patients was assessed by a clinical score “modified Wexner score”, on a scale from 0 to 24 , with 0 means complete continence and 24 means complete incontinence. **Results:** the mean age of the study was 23.9±11.2. The continence score after 6 months was ranging between 0 and 9 , with majority of the cases were between 2 and 6. **Conclusion:** there are many factors that influence the treatment outcomes regarding anal continence including the mode of trauma, type and site of injury and the operative procedure. Primary repair of traumatic anal sphincter injury can be done in the emergency settings, unless there is severe and extensive destruction of the perineal soft tissue. Long term follow up of the patients with anal sphincter injury and the use of recent diagnostic modalities such as anal manometry and endoanal ultrasound can lead to more dependable and precise results about fecal incontinence.

Key words: Perineum, Anorectum, Trauma, Fecal incontinence, overlapping sphinctroplasty.

Introduction

Perineal injuries due to accidental traumas are not very common in the trauma and emergency settings, but not rare at the same time . And when we encounter such type of trauma, it needs to be managed according to clear, systematic guidelines taking in consideration the anatomical orientation among adjacent structure and possible associated injuries⁽¹⁾

The different aetiologies of perineal injures include iatrogenic causes such as haemorrhoidectomy, fistulctomy, fissurectomy and also during normal delivery.

Blunt trauma is considered an infrequent cause of perineal and anorectal injury (5- 10%). This infrequent type of injury is usually caused by motor vehicle, motorcycle or pedestrian-vehicular accidents⁽²⁾

One of the main morbidities that perineal and anorectal trauma casualties suffer from is fecal incontinence which could be disabling and devastating to the degree that permanent fecal diversion in some severe cases will be a reasonable option for patient satisfaction⁽³⁾

Restoring normal and satisfactory bowel function and anal continence after such type of injuries are the primary outcome addressed in the present study, by which we can evaluate the competence and degree of success of our management.

Patients and methods**1. Study participants**

This study has been conducted in El-Minia university hospital, emergency unit including

32 patients in the period between March 2021 and December 2021.

All the patients had come to the E.R presented with perineal trauma of different aetiologies and modes of trauma.

2. Inclusion criteria

- 1) All patients sustained acute perineal injuries.
- 2) Patients of both genders and age range from 6 to 60 years old.
- 3) All possible mechanisms of trauma (Blunt, penetrating, iatrogenic anal sphincter injuries and obstetric anal sphincter injuries)

3. Exclusion criteria:

- 1) Chronic anal sphincter dysfunction as they need different advanced modalities for diagnosis.
- 2) Children below the age of six.

Methodology

Pre-operative preparations.

- Primary survey according to ATLS protocol especially in polytrauma patients to ensure that immediate life-threatening injuries are stabilized.

- Resuscitation and hemorrhage control.

- Stabilization of the pelvis if fractures present.

- During the secondary survey, perineal and anorectal trauma can be assessed and evaluated:

1- History taking: history related to the injury, associated symptoms including abdominal and genitourinary symptoms, as well as baseline bowel function and continence can be helpful. Particularly for penetrating injuries, knowing the caliber and velocity of the missile can help establish an understanding of the potential injury.

2- Physical examination: begins with visual inspection, including an assessment of the site of injury, corrugation of perianal skin, entry and exit wounds in the penetrating trauma patient and bleeding per anum or urethra.

Palpation of the perineal region for assessing the depth of the injury and extent of tissue involvement.

Digital rectal examination should also include an assessment of resting and squeeze tone when feasible and presence of a palpable sphincteric defect or anorectal tears.

Examination under anesthesia in the operative theatre was done to all patients in lithotomy

position and in some cases proctoscopy was used.

- Exclusion of associated rectal, bowel and other organ injury through history, examination and available investigations.

Laboratory investigation:

The usual laboratory investigations in trauma patients were done including:

- complete blood count (CBC)
- Blood grouping and matching
- coagulation profile
- Renal function test

Imaging:

- Plain x-ray: pelvis , Abdomen erect
- Abdominal U/S: exclude abdominal visceral injury
- Contrast studies: contrast enema to exclude rectal or colon perforation
- C.T Abdomen and pelvis with contrast

Operative procedure

Variable operative procedures had been done according to the severity , extent of the injury and associated organ injuries.

The procedure was performed in most of the cases under spinal anesthesia and only few needed general anesthesia in which exploratory laparotomy was planned or another surgical intervention was needed for associated injury. All patients received routine preoperative antibiotic prophylaxis (third generation cephalosporin).

After Examination under anesthesia and thorough assessment of the injury were done, we chose the surgical treatment compatible with the severity and extent of injury.

- **Primary repair** of external anal sphincter injury by overlapping technique.
- **Fecal diversion** (defunctioning colostomy) will be needed if there is severe damage to anal sphincter complex or extensive perineal tissue loss or severe debilitating injury.
- **Perineal wound care:** Perineal wounds range from minor skin penetration requiring debridement only to major lacerations with extensively degloved soft tissues.

- All cyanotic devitalized tissue and the most severely bruised tissue was debrided at initial exploration because such tissue damage can be expected to lead to necrosis, and then to pelvic sepsis. Debridement extended to tissues that have vigorous, bright- red bleeding , further tissue damage have been

watched for during daily exploration and dressing of the wound .Once it is certain that no further necrosis of the anal canal will occur, reconstruction can be performed .

- **Exploratory laparotomy** was done in some cases in which abdominal visceral injury was suspected.

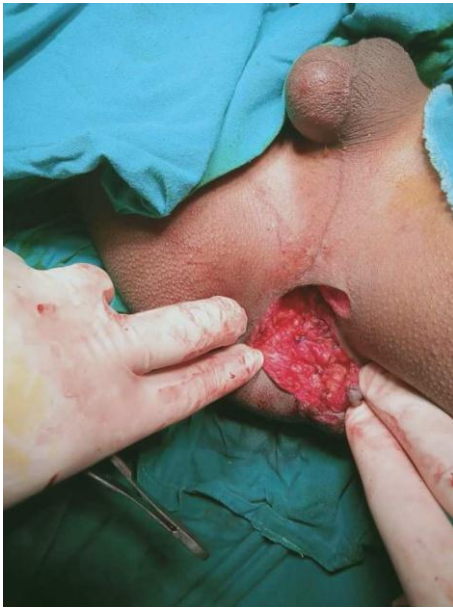

Figure 1: After repair of sphincter by overlapping technique

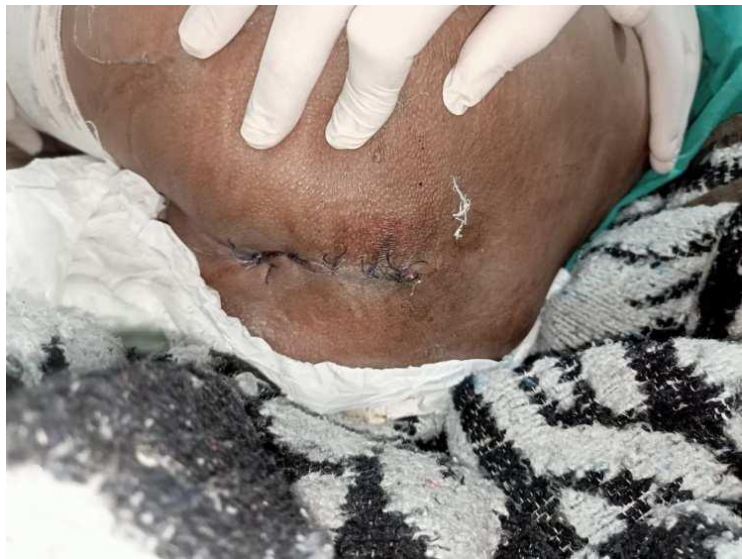

Figure 2: primary wound closure

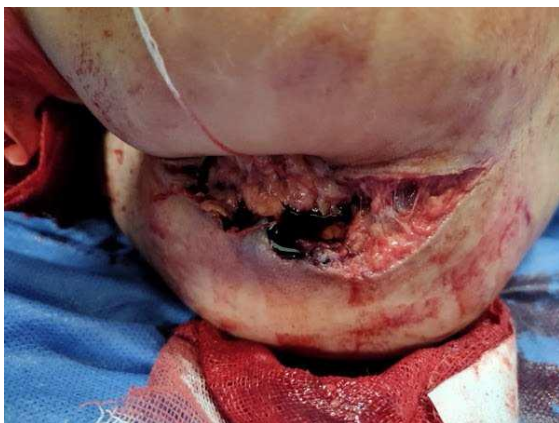

Figure 3: Severe perineal injury

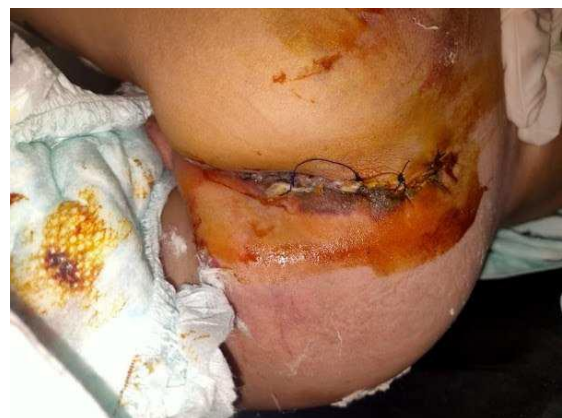

Figure 4: After repair

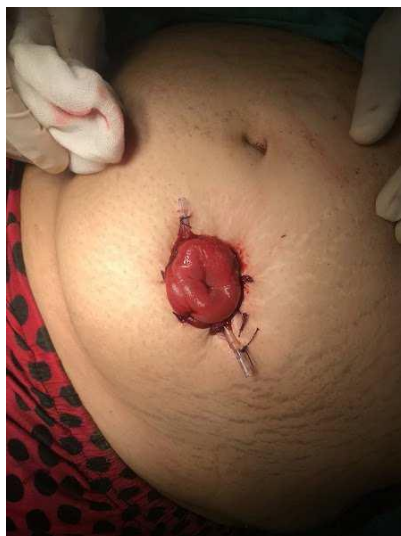

Figure 5: Defunctioning sigmoid colostomy done in the previous case

Postoperative follow-up:

The patients had been followed up for a duration ranging from 1 month up to 6 months.

Early, Patients were checked for:

- Perineal wound related complications: infection, sepsis, need for further debridement, and need for reconstruction.
- Early postoperative baseline fecal continence.

Late, Patients were followed up for degree of fecal incontinence evidenced by:

1- History taking: using the “modified Wexner’s score” or “Vaizey’s score” for fecal incontinence to detect its severity we assessed the patient continence status at different times: early post-operative, after 1 month, after 3 months and after 6 months.

2- Physical Examination: DRE: resting & squeezing anal tone, presence of any defect or scar tissue.

3- Patient’s satisfaction and quality of life.

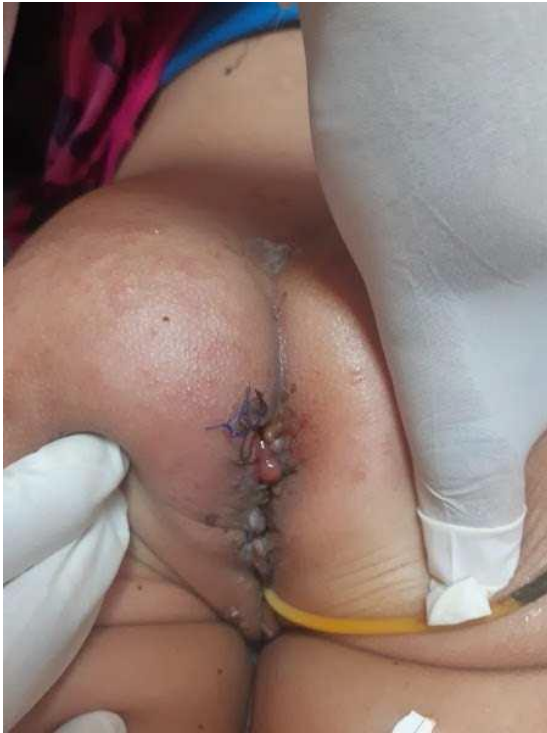

Figure 6: first follow up visit

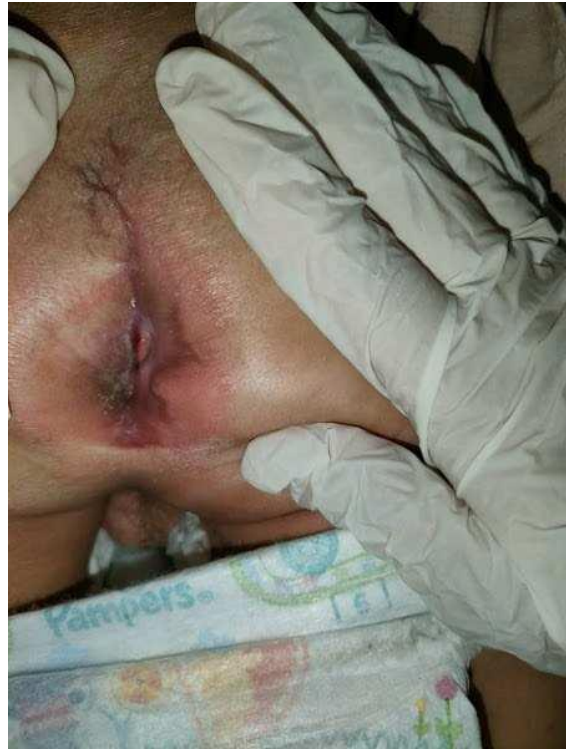

Figure 7: after 3 months

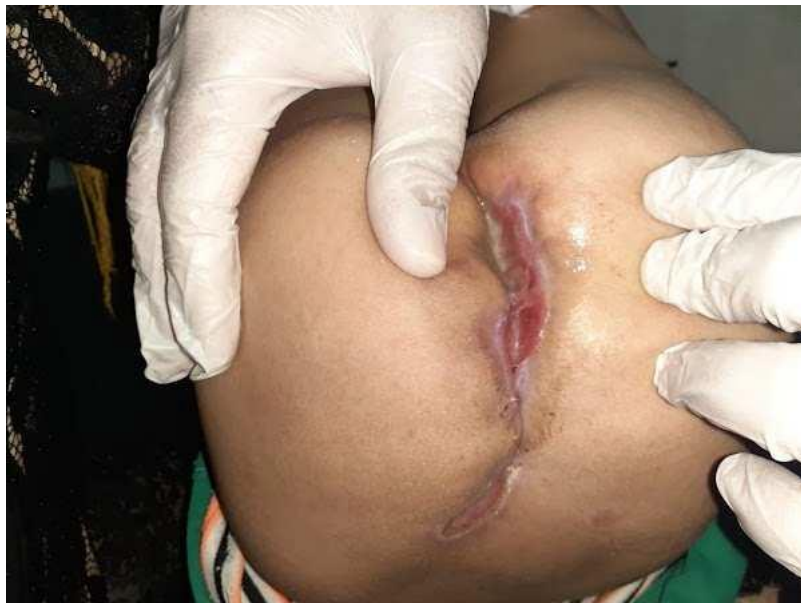

Figure 8: after 6 months

Results

1. Age and sex of patients

The total number of patients included in this study was 32. Males were equal to females,

each comprising 50 % (N=16) . The age of the patients ranged between 6 & 40 years old, the mean age of the study was 23.9 ± 11.2 , and median age was 29 . (Figure 9).

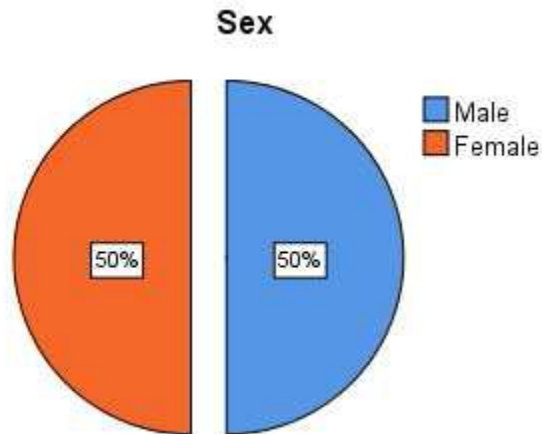


Figure 9: Pie chart showing distribution of sex of studied patients

2. Mode of trauma

Many different modes of trauma were included in the study as a cause for peineal injury, post vaginal delivery (N=10) representing 31 % was the most common cause.

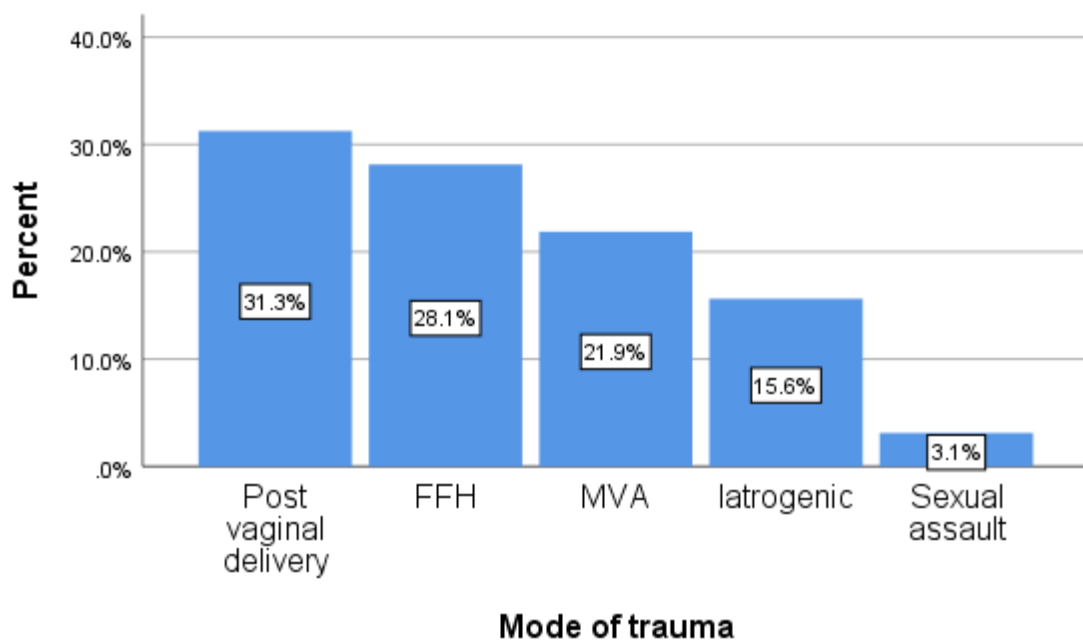


Figure 10: Bar chart showing mode of trauma among studied patients.

3. Site of sphincter injury among studied patients

The site of injury in the studied patients was described after examination in lithotomy position, with anal canal forming a complete circle traversed by imaginary line between 3 & 9 o'clock which divided the injuries into anterior, posterior, lateral and total. Anterior injury was the most frequent site of injury in the study representing 53.1.

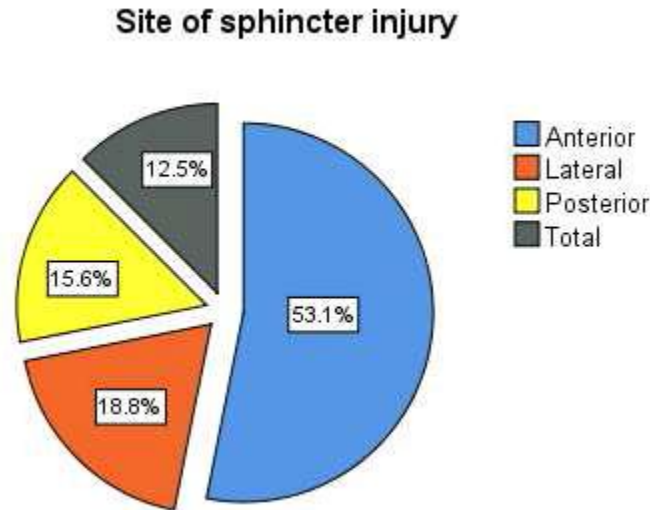


Figure 10: Pie chart showing site of sphincter injury among studied patients.

4. Operative procedures

The main operative treatment applied in the study was immediate 1ry repair in the emergency setting with or without bowel diversion according to our evaluation to each individual case. The non-diverted cases comprised the main bulk of patients, representing 75% (N=24).

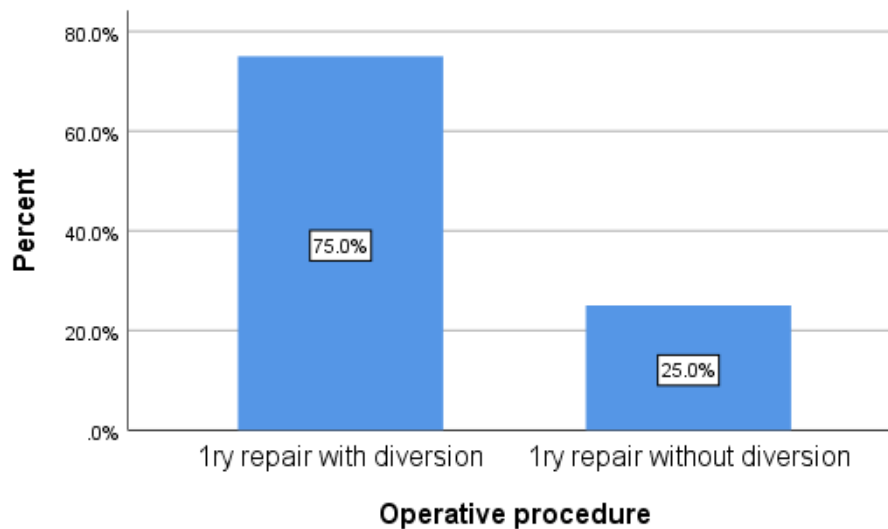


Figure 11: Operative procedures.

7. Frequency of wound complications

One of the main and frequent problems of wounds in such body region, the perineum, is wound infection and subsequent wound complications. (Jeganathan et al., 2018). Wound complications in the studied patients represents about 40.6 % , all of which were wound infections which treated only by repeated dressing and topical antimicrobial agents.

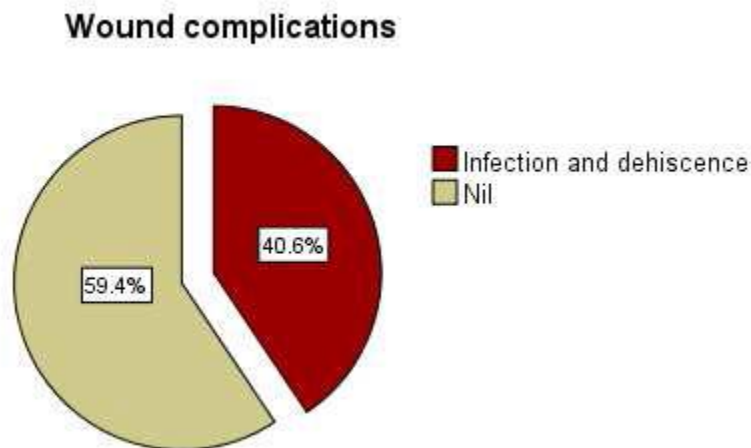


Figure 12: Pie chart of wound complications

8. Modified Wexner score:

The post-operative continence in the studied patients was measured by modified Wexner score on a scale from 0 to 24 , with 0 means complete continence and 24 means complete incontinence . The studied patients were evaluated post operatively by the score at intervals of 1, 3 and 6 months. The continence score after 6 months was ranging between 0 and 9 , with majority of the cases were between 2 and 6.

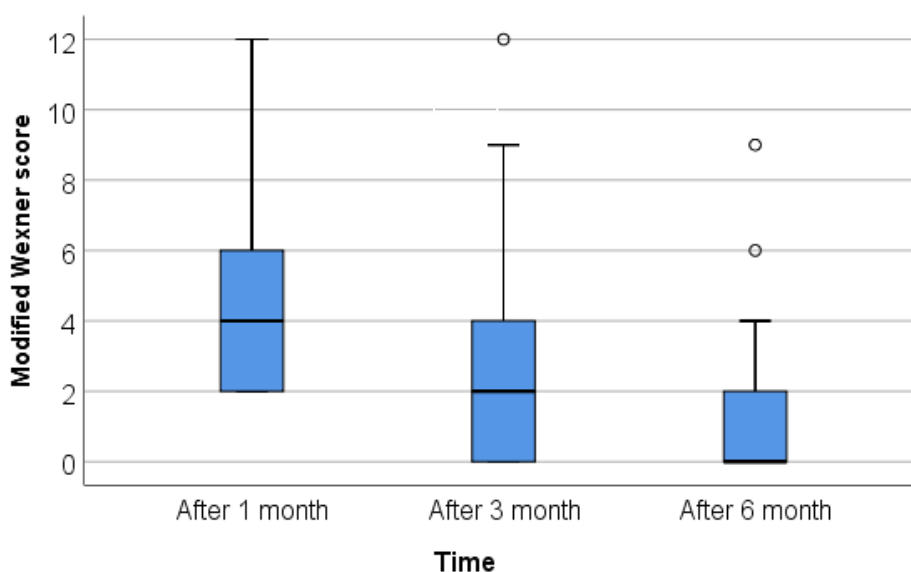


Fig 13 : Box plot showing median and IQR of modified Wexner score

Discussion

We have dealt in this study with various types of perineal injuries of different aetiologies Regarding age of the studied patients in our research, the median age was 29 years old, most of them were children and young adults. Our results and results from other similar studies

suggesting that the younger the age of the patient with such type of injury, the better the end result will be regarding continence score. Healthiness and integrity and proper thickness of perineal muscles as well as good healing power in younger ages could explain our findings.⁽⁴⁾

In the current study, we had equal number of male and female patients having been treated from perineal injuries. Obstetric trauma as a major cause of sphincter injury explains the high incidence and wide prevalence of this type of injury in females.⁽⁵⁾

We had included in this study all different modes of trauma that causes perineal injury, obstetric trauma was the most frequent mode of trauma we had dealt with during our research, comprising about 31 % of all cases. While in the second place came blunt perineal injuries caused by road traffic accidents, falling astride or straddling traumas, followed by iatrogenic injuries during anorectal operations.

Many other studies presented obstetric trauma as a major cause of anal sphincter injury and anal incontinence.⁽⁶⁾

Obstetric anal sphincter injury is a truly distressing problem in the field of obstetrics practice. Reports suggest that obstetric anal sphincter damage complicates as many as 35 percent of primiparous vaginal deliveries, with 13 percent of first-time mothers becoming symptomatic. Some injuries are obvious and easily recognizable such as 3rd and 4th degree perineal tears. However subtle injuries can be present and are not recognizable unless advanced investigations used such as EAUS (endo-anal ultrasound).⁽⁷⁾

Regarding Iatrogenic sphincter injury ; many surgical anal procedures are incriminated in such injuries causing post-operative fecal incontinence such as anal fistula surgery, hemorrhoidectomy and lateral sphincterotomy⁽⁸⁾. According to this study anal fistula surgery was the procedure associated with a higher incidence of sphincter injury than other anal procedures.

Perineal Injuries due to blunt pelvi-perineal trauma was the worst type in both dealing with as a management and later as the final outcome after treatment. Such type of injury that may be caused by road traffic accidents , falling from height or straddling traumas , usually lead to more destructive and devastating injuries to the perineum which could be associated with anorectal or other visceral abdominal injury , urogenital injury and orthopedic injury as well (e.g. fracture pelvis, femur).

In the current study we dealt with 10 cases with blunt perineal trauma comprising about 31%. The median Wexner's score of incontinence in such injuries after 6 months was 5; which is considered the worst among other types of injury. One case has an associated fracture femur and other two cases had an associated fracture pelvis; which warranted a surgical orthopedic intervention.

All the cases included in our study had an associated anal sphincter injury, which we had classified it according to its site to anterior, lateral, posterior and total. By examination in lithotomy position; with anal canal forming a complete circle traversed by imaginary line between 3 & 9 o'clock which divided the injuries into anterior, posterior, lateral, while in total injury it's all-around with floating anus. This total injury which was associated mostly with blunt perineal traumas; led to the worst final outcome regarding fecal incontinence. However, anterior injury was the most frequent in this study.

The main principle in the operative management of the studied cases was to primary repair the perineum and anal sphincter in the emergency setting whenever the patient's condition allows, in addition to doing a colonic diversion or not according to the assessment of each case separately and individually.

In this study it was amenable to primary repair the perineal wound and the anal sphincter in all of our cases after proper debridement of the devitalized tissue and generous rinsing and irrigating by saline and sterilizing agent to disinfect and sterilize the wound. We did the primary repair of the anal sphincter by **overlapping technique** in most of the cases, which was an amenable procedure as we did not face an extensive tissue loss or severe devastating perineal injuries.

Another one-year long study done by Fernando et al. concluded that primary overlapping repair of the external anal sphincter compared with primary end-to-end repair appears to be associated with lower risks of developing fecal urgency and anal incontinence symptoms.⁽⁷⁾

We have chosen to do a diverting colostomy in selected cases (25%) after we had intra-operatively assessed the injury regarding the

extent and severity of perineal injury, presence of associated anorectal injury and presence of any other disabling injury such as fracture pelvis or genitourinary injury.

Although there is still some controversy the preference of primary repair than colostomy, results from recent studies are compatible with this study in the trend of treating most of the simple cases without diversion and leaving the management with diverting colostomy to limited indicated cases.⁽⁹⁾

All the studied cases underwent continence assessment upon modified Wexner's score at intervals 1,3 and 6 months postoperative. The results obtained from our cases showed reasonable success and satisfying outcome with mean score after 6 month-follow up was 1.7 ± 2.5 . However, there was an acceptable range of variation in the final score among the cases which we could relate it with the difference of severity of trauma, type & site of injury and operative procedure.

A study of fecal incontinence after repair of obstetric anal sphincter injury measured also by modified Wexner's score stated that a mean score of 2.1 after 6 months; was considered satisfactory and indicator for successful management.⁽¹⁰⁾

In about 25 % of cases, A colonic diversion was necessary in the management of their injuries to allow proper healing of a repaired sphincter or anorectal tear and to lower the possibilities of wound infection. However incontinence score results seemed to be worse in the diverted group of patients than the non-diverted group.

From the results of the current study; we assume that this association could be primarily related to the aetiology, the severity and extent of injury that dictated doing a diversion in the first place.

Levine JH, et al, declared that a colostomy is not always necessary. The depth of the wound and the degree of soft-tissue loss or contamination should be evaluated.

If there is doubt about the presence or extent of a rectal injury, then fecal diversion with or without repair would be the best choice.⁽¹¹⁾

Conclusion

According to the results of the present study; there are many factors that influence the treatment outcomes regarding anal continence. These factors include the mode of trauma, type and site of injury and the operative procedure.

Regarding site of injury; total sphincter injury or multiple injuries at different sites are the worst types in the degree of post-operative incontinence.

Fecal incontinence is a very distressing problem that affects quality of life and has social aspects. A plan of treatment is tailored to each case individually according to the assessment of the severity and extent of the perineal injury, whether the perineal wound and sphincter injury could be primary repaired or not, and if there is a need for fecal diversion or not.

This study recommends that primary repair of traumatic anal sphincter injury can be done in the emergency settings, unless there is severe and extensive destruction of the perineal soft tissue. Fecal diversion is done selectively in case of presence of extensive soft tissue damage and association of anorectal or disabling injury.

Long term follow up of the patients with anal sphincter injury and the use of recent diagnostic modalities such as anal manometry and endoanal ultrasound can lead to more dependable and precise results about fecal incontinence.

References

1. Kudsk, K. A. & hanna, M. K. Management of complex perineal Injuries. World journal of surgery, 2003; 27, 895-900
2. Cleary, R. K., pomerantz, R. A. & lampman, R. M. Colon and Rectal injuries. Diseases of the colon & rectum, 2006;49, 1203-1222
3. Bartolo, D. & Macdonald, A. Fecal continence and defecation. The Pelvic Floor, its functions and disorders. Eds Pemberton J, Swash M, and Henry MM, WB Saunders, London,2002; 77-83.
4. Edwards, N. I. & jones, d. The prevalence of faecal incontinence in Older people living at home. Age and ageing, 2001;30, 503-507

5. Turel Fatakia F, Subramaniam N, Bienkiewicz J, Friedman T, Dietz HP. How repeatable is assessment of external anal sphincter trauma by exoanal 4D ultrasound? *Ultrasound Obstet Gynecol* 2019;53:836–840.
6. Fernando RJ, Sultan AH, Kettle C, Thakar R. Methods of repair for obstetric anal sphincter injury. *Cochrane Database Syst Rev*. 2013 Dec 8;(12):CD002866.
7. Halverson AL, Hull TL. Long-term outcome of overlapping anal sphincter repair. *Dis Colon Rectum*. 2002 Mar; 45(3):345-8.
8. Fernando, R. J., sultan, A. H., kettle, C., radley, S., Jones, P. & O'brien, P. M. 2006. Repair techniques for obstetric anal sphincter injuries: A randomized controlled trial. *Obstetrics & gynecology*, 107, 1261-1268.
9. Bollard, R. C., gardiner, J., duthie, G. S. & lindow, S. W. 2003. Anal Sphincter injury, fecal and urinary incontinence. *Diseases of the colon & Rectum*, 2003;46, 1083-1088.
10. Levine, J. H., longo, W. E., pruit, C., mazuski, J. E., shapiro, M. J. & Turel, F. D., langer, S., shek, K. L. & Dietz, H. P. 2019. Medium-to longterm Follow-up of obstetric anal sphincter injury. *Diseases of the colon & Rectum*, 62, 348-356.