

Research Article

Evaluation of the effect of using Autogenous Partially Demineralized Dentin Matrix (APDDM) versus xenograft around Immediate Implant (Randomized clinical Study)

Mahmoud S. Ali* and Ahmed A. Khalil*

* Department of Oral Diagnosis and Periodontology, Faculty of Dentistry _ Minia University

Abstract

There is a growing tendency to place single tooth implants immediately after extracting a failing tooth in the posterior region. The aim of this prospective case series pilot study was to evaluate immediate implant placement in molar-premolar post-extraction sites during a 1-year follow-up period. **Aim of the study:** To evaluate the effect of using Autogenous Partially Demineralized Dentin Matrix (APDDM) versus xenograft around Immediate implant. **Patients and methods:** twelve patients who have bilateral badly decayed tooth in premolar-molar area in a split mouth study. Group I: includes 12 Immediate implant in one side with autogenous partially demineralized dentin matrix (APDDM) as a grafting material around the implant. **Group II:** includes 12 Immediate implant in the other side with Xenograft as a grafting material around the implant. Following parameters will be evaluated before treatment and recorded at baseline and after 6 months Plaque index (PI), Bleeding index (BI), Gingival recession (GR), Probing depth (PD), Conebeam Ct radiograph at baseline, 6 month and 12month. **Results:** Four out of 15 of the mobile implants had to be removed before the 1-year evaluation. The implant and restoration survival rates were 73.3% at the 1-year evaluation (n = 15). The mean marginal bone loss, from loading to the 12-month follow-up, was 0.17 mm (n = 11). The mean plaque, calculus, peri-implant mucosa, bleeding, and pocket probing depth scores were low, depicting healthy peri-implant conditions. The patients were very satisfied. **Conclusion:** The placement of immediate implants in the posterior sector is a widespread procedure where the success and survival rates are similar to those of traditional protocols. It has several anatomical challenges, such as the presence of interradicular bone septa that hinder a correct three-dimensional positioning of the implant and may compromise primary stability and/or cause damage of neighboring structures. The aim of this article is to present the treatment and the one-year clinical follow-up of a patient who received immediate implant placement using an interradicular bone-drilling technique before the molar extraction

Keywords: Immediate implant, Dentin graft, xenograft.**Introduction**

Implant therapy is currently considered a successful and acceptable means to restore missing teeth. During the decades that have passed since the widespread acceptance of implant dentistry, placement protocols have evolved to vary the timing of implant placement from late (in completely healed sites) through delayed and, finally, immediate placement following extraction. These procedures were developed to better meet patients' expectations⁽¹⁾.

The implant placement classified into immediate⁽²⁾, recent, delayed, and mature to describe the timing of implant placement in relation to soft tissue healing and predictability of guided bone regeneration procedures⁽³⁾.

Immediate implantation defined as implants placed between 3 and 15 days (mean 10 days) following tooth extraction⁽⁴⁾. While delayed implant placement occur between 6 weeks and 6 months after extraction⁽⁵⁾.

The advantages of immediate implant placement are a reduction in the number of surgical procedures and treatment time required, preservation of the bone at the extraction site, and optimal soft-tissue esthetics. Furthermore, there is evidence that immediate implant placement is a predictable alternative to conventional placement, with high success rates reported over 4-11- year observation periods⁽⁶⁾. In spite of advanced diagnostic facilities, it is a real challenge to place an implant matching the extracted tooth dimensions. The space between the implant and bone is required to be filled in three dimensions with a biocompatible material for enhanced osseointegration⁽⁷⁾.

The recent popularity of implant dentistry has led to an increasing demand for alveolar bone regeneration. Autogenous bone grafting is still the gold standard for bone augmentation because it is excellent in osteogenesis but it has some impediments such as limited availability, donor site morbidity, and also high resorption rates of up to 50%. Alternative graft materials including allografts, xenografts, and alloplastic bone grafts are clinically used, but they have disadvantages such as high cost and limited osteoinductivity. Among these, demineralized freeze-dried bone allografts (DFDBAs) have been widely used for alveolar bone augmentation because of their natural structure and inclusion of growth factors such as bone morphogenetic proteins (BMPs), DFDBA carries the risk of disease transmission. Thus, development of an alternative material that overcomes these shortcomings is expected⁽⁸⁾.

BMPs are growth factors that naturally found within the bone matrix and act as pleiotropic organizer of chemotaxis mitosis, differentiation, excitation of extracellular matrix formation, bound to matrix components, conservation of phenotype, and apoptosis. In addition, they play a role in regulation of bone volume, skeletal organogenesis and the regeneration of bone after a fracture⁽⁹⁾.

The structure and composition of dentin are similar to that of bone, so it is thought to have significant osteoconductivity. Furthermore, dentin matrix has some osteoinductivity because it contains BMPs thus, dentin or dentin matrix is expected to serve as a bone substitute. Some studies have shown that mineralized

dentin matrix possesses excellent biocompatibility, but is less effective in bone formation than bone derived products. However, several animal studies showed that demineralized dentin matrix (DDM) is not only biocompatible but also osteoinductive, similar to demineralized bone matrix⁽⁸⁾.

Dentin also contains some growth factors common to a bone, namely, insulin-like growth factor-II, bone morphogenetic protein (BMP), and transforming growth factor-beta.⁽¹⁰⁾

Autogenous DDM has shown potential applications in bone substitute and scaffold. The advantage is its low morbidity, easy handling, and great radiopacity and enhances bone-remodelling capabilities also there is the absence of antigenicity.⁽¹¹⁾

Dentin has been shown to be a potential carrier for human proteins and as grafting material because its biological composition is very similar to that of alveolar bone. Both tooth and alveolar bone are derived from neural crest cells and are made up of the same type I collagen⁽¹²⁾. The clinical application of autogenous sliced DDM to the extraction socket of mandibular third molar showed slightly better healing of the sockets⁽¹³⁾

Patients and Methods

This study will be conducted on twelve patients who have bilateral badly decayed tooth in premolar-molar area in a split mouth study. The entire patient will be selected from the out patients clinic of oral medicine, oral Diagnosis and Periodontology Department, Faculty of Dentistry, Minia University.

(I) Ethical regulations: The complete treatment plan was explained to all patients including detailed steps, risks, and expected results, and their full signed consent will be obtained before entry into the study. The study complied with the rules set by the International Conference on Harmonization Good Clinical Practice Guidelines, and the Declaration of Helsinki. The study was approved by the research ethics committee of the Faculty of Dentistry, Minia University.

(II) Patient selection: Selected patients of both sexes are 25-55 years old. Patients have bilateral badly decayed tooth in split mouth design.

Patients are free from any systemic diseases that might affect healing, or complicate the surgical procedures according to modified Cornell Medical Index (Glick M., 2003)

No antibiotics or any medication that affect bone or soft tissue condition taken during the last six months

(I) Treatment protocol: Group I: includes 12 Immediate implant in one side with autogenous partially demineralized dentin matrix (APDDM) as a grafting material around the implant.

Preparation of dentine graft (for group I): ⁽¹⁴⁾

- 1- After extraction of the tooth, any pulp tissue or root canal filling will be removed by k file and rotary system.
- 2- By using diamond bur, cleaning of the root from any remnant of PDL, calculus, cementum and removal of enamel will be done.
- 3- The remaining dentine will be cut into pieces and grind with bone mill.
- 4- The collected dentine will be immersed for 10 minutes in small sterile glass container which include inside it basic

alcohol consist of (0.5M NAOH and 3% alcohol (V/V) to dissolve debris, bacteria and toxins.

- 5- The dentine particulate will be washed in sterile phosphate buffered saline leaving wet particulate dentine mixed with autogeneous blood and ready for graft.

Group II: includes 12 Immediate implant in the other side with Xenograft as a grafting material around the implant

(I) Assessment method: both groups were evaluated clinically regularly at 6 (after surgery), and 12 months post-operative. Every patient was assessed by the following clinical parameters include PI, GI, PD.

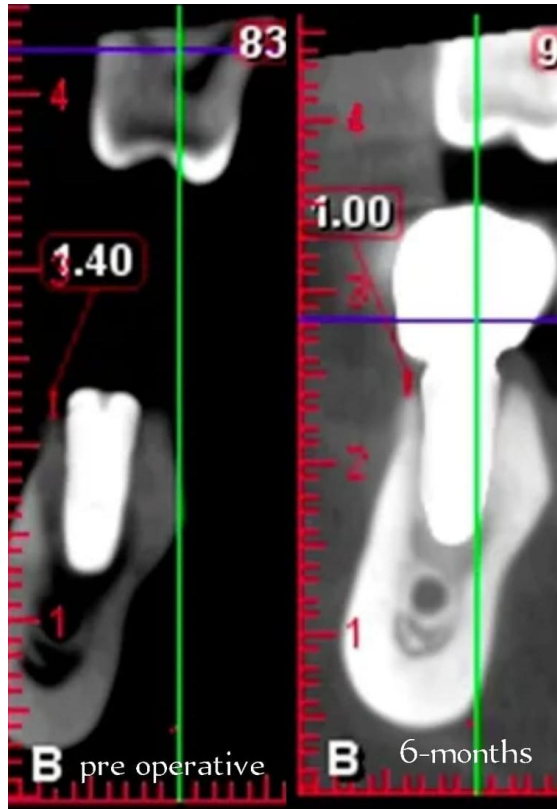
Results

Frequencies and percentages of plaque index scores (possible score 0–3), calculus index scores (possible score 0–1), gingival index scores (possible score 0–3), bleeding index scores (possible score 0–3), and mean value and standard deviation of probing depth (in mm) 1 month after restoration placement (T1) and after 1 year (T12)

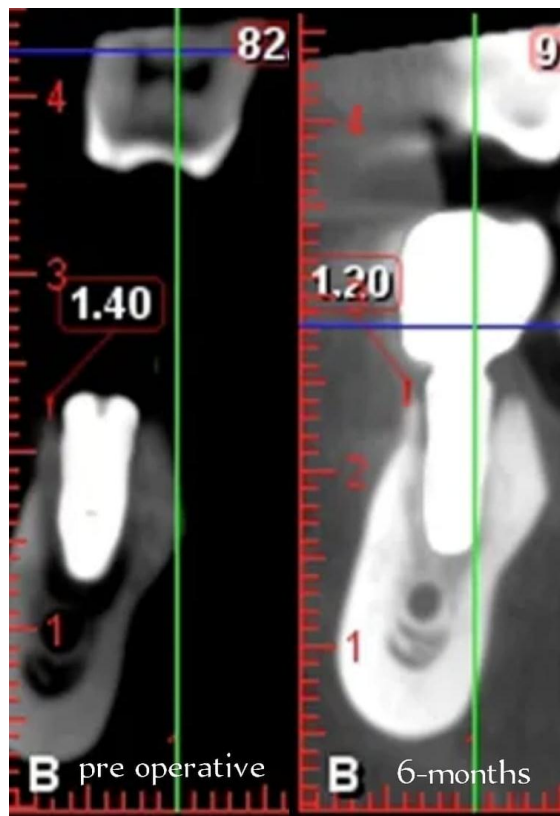
	T1 (n = 15)	T12 (n = 11)
plaque index scores	Score 0, 15 (100%)	Score 0, 11 (100%)
gingival index scores	Score 0, 15 (100%)	Score 0, 11 (100%)
bleeding index scores	Score 0, 15 (100%)	Score 0, 10 (91%)
Probing depth in mm	2.0 (0.9)	1.9 (0.8)
Calculus index Score	Score 0, 15 (100%)	Score 0, 11 (100%)

Mean value, standard deviation, and frequency distribution (percentages) of marginal bone level at 1 month after restoration placement (T1)

Bone level (mm)	n = 15
Mean (SD)	- 0.94 mm (0.54)
> - 2.5 to - 2.0	1 (6.7)
> - 2.0 to - 1.5	2 (13.3)
> - 1.5 to - 1.0	4 (26.7)
> - 1.0 to - 0.5	5 (33.3)
> - 1.0 to - 0.5	5 (33.3)



Xenograft (pre operative / 6-months follow up) (group 1)



Dentin graft (pre operative / 6-months follow up) (group 2)

Discussion

Immediate placement of regular diameter implants in molar post-extraction sites of the mandible resulted in a high implant failure rate during a 1-year follow-up period. The implant survival rate was 73.3% after 1 year in function. The performance of immediate placements in post-extraction sites was also analysed in the Cafiero et al., Atieh et al., Tallarico et al., and Checchi et al. prospective 1-year studies^(15,16) They reported a 1- year implant survival rate of 100%, 66.7%, 100%, and 89.4%, respectively. In the present study, an implant diameter of 4.3 mm was used in all the patients; the aforementioned studies used implant diameters of 4.8 mm, 8–9 mm, 7 mm, and 6–8 mm, respectively. The Atieh et al.,⁽¹⁵⁾ implant survival rate was the lowest (66.7%) and comparable with the survival rate in the present study, but it must be mentioned that the implant placement was combined with immediate provisionalization, whereas in the other studies, the implants were restored after 3–6 months. It was reported that implant stability in healed bone in the early postoperative period is positively influenced by the macro-thread design. A large thread depth with sharp thread edges and a small thread pitch (distance between two threads) gives higher implant stability than a small thread depth with v shaped edges and large thread pitch. The mean marginal bone level was 0.94 mm below the neck of the implant at 1 month after restoration placement (T1). The optimal position of the peri-implant bone after a maturation period should be at the same level as the neck of the implant. This means that part of the biological width of the present study, which is acting as a barrier, was in contact with the implant surface roughness and was therefore more prone to biofilm formation, soft tissue infection, and peri-implantitis. Apparently, the large gap between the socket wall and the regular diameter implant, notwithstanding the local augmentation procedure, did not fill completely during healing which led to a compromised bone level.

The Checchi et al.,⁽¹⁷⁾ study also mentioned that the bone level at the commencement of loading was 0.43 mm apically of the implant neck, possibly confirming the idea that better initial bone levels are reached with wider implants.

The mean change of the marginal bone height during the 1-year follow-up was – 0.17 mm, which is very limited. The Tallarico et al., and Checchi et al. studies' periimplant bone loss⁽¹⁷⁾ was 0.23 mm and 0.68 mm respectively, from initial loading to the 1-year evaluation. Apparently, after the period of healing and maturation peri-implant, bone levels remain rather stable. Zirconia restorations are presumed to be highly biocompatible and can potentially attach to soft-tissue. It is claimed that zirconia promotes the attachment of human gingival fibroblasts in vivo, which is desirable because it mimics tooth cementum's ability to attach to gingiva, forming the junctional epithelium⁽¹⁸⁾. With respect to the evaluation items of the peri-implant soft tissues of the present study, the findings are consistent with a healthy status, confirming the high biocompatibility of the material. The limited probing depth (mean value of 1.9 mm at the 1-year evaluation) is possibly associated with the claimed soft-tissue attachment potential

Conclusion

Within the limitations of this study, it has been demonstrated that immediate placement of regular diameter implants in molar post-extraction sites of maxilla and mandible resulted in a high implant failure rate during a 1-year follow-up period

Reference

- 1- Branemark PI, Adell R, Breine U, Hansson BO, Lindstrom J, Ohlsson A. Intra-osseous anchorage of dental prostheses I. Experimental studies. *Scand J Plast Reconstr Surg* 1969; 3:81–100.
- 2- Wilson TG, Weber HP. Classification and therapy for areas of deficient bony housing prior to dental implant placement. *Int J Periodontics Restorative Dent.* 1993; 13: 451–459.
- 3- Pal U. S., Kumar N. D., Singh G., Singh R. K., Mohammad S., Laxman R. Evaluation of implants placed immediately or delayed into extraction sites. *Natl J Maxillofac Surg.* 2011; 2: 54–62.
- 4- Schropp, Lars, Lambros Kostopoulos, and Ann Wenzel. Bone healing following immediate versus delayed placement of titanium implants into extraction sockets: A prospective clinical study. *Int. J. Oral Maxillofacial Implants.* 2003;182:189–99.

- 5- Zitzmann NU, Naef R, Scharer P. Resorbable versus nonresorbable membranes in combination with Bio-oss for guided bone regeneration. *Int J Oral Maxillofacial Implants.* 1997;12:844–52.
- 6- Hassan, K. S. Autogenous bone graft combined with polylactic polyglycolic acid polymer for treatment of dehiscence around immediate dental implants. *Oral Surgery, Oral Medicine, Oral Pathology, Oral Radiology, and Endodontology*, 2009, 108.5: e19-e25.
- 7- Viswambaran, M., Arora, V., Tripathi, R. C., & Dhiman, R. K. Clinical evaluation of immediate implants using different types of bone augmentation materials. *medical journal armed forces india*, 2014, 70.2: 154-162.
- 8- Minamizato, T., Koga, T., Takashi, I., Nakatani, Y., Umebayashi, M., Sumita, Y., ... & Asahina, I. Clinical application of autogenous partially demineralized dentin matrix prepared immediately after extraction for alveolar bone regeneration in implant dentistry: a pilot study. *International journal of oral and maxillofacial surgery*, 2018, 47.1: 125-132.
- 9- Valdes MA, Th akur NA, Namdari S, Ciombor DM, Palumbo M. Recombinant bone morphogenic protein-2 in orthopaedic surgery: A review. *Arch Orthop Trauma Surg*2009;129:1651-7.
- 10- Sarala C, Chauhan M, Sandhya PS, Dharmendra CH, Mitra N. Autogenous tooth bone graft: Ingenious boneregeneration material. *Indian J Dent Sci.* 2018;10 (1):56-59.
- 11- Al-Asfour A, Farzad P, Al-Musawi A, Dahlin C, Andersson L. Demineralized xenogenic dentin and autogenous bone as onlay grafts to rabbit tibia. *Implant Dent.* 2017;26(2):232-237
- 12- Aparicio C. The use of the periotest value as the initial success criteria of an implant: 8-years report. *Int. J. Periodontics Restorative Dent.* 1997;17:150-161.(PupMed)
- 13- Gomes MF, Abreu PP, Morosolli AR, Araujo MM, Goulart MD. Densitometric analysis of the autogenous demineralized dentin matrix on the dental socket wound healing process in humans. *Braz Oral Res.* 2006; 20(4): 324–330.
- 14- Tabatabaei FS, Tatari S, Samadi R, Moharamzadeh K. Different methods of dentin processing for application in bone tissue engineering: A systematic review. *J Biomed Mater Res A.* 2016;104(10):2616-27
- 15- Atieh MA, Alsabeeha NH, Duncan WJ, de Silva RK, Cullinan MP, Schwass D, Payne AG. Immediate single implant restorations in mandibular molar extraction sockets: a controlled clinical trial. *Clin Oral Implants Res.* 2013;24: 484–96. <https://doi.org/10.1111/j.1600-0501.2011.02415.x>.
- 16- Cafiero C, Annibali S, Gherlone E, Grassi FR, Gualini F, Magliano A, Romeo E, Tonelli P, Lang NP, Salvi GE. Immediate transmucosal implant placement in molar extraction sites: a 12-month prospective multicenter cohort study. *Clin Oral Implants Res.* 2008;19:476–82. <https://doi.org/10.1111/j.1600-0501.2008.01541.x>.
- 17- Tallarico M, Khanari E, Pisano M, Gatti F, Meloni SM. Molar replacement with 7 mm-wide diameter implants: to place the implant immediately or to wait 4 months after socket preservation? 1 year after loading results from a randomised controlled trial. *Eur J Oral Implantol.* 2017;10:169–78.
- 18- Checchi V, Felice P, Zucchelli G, Barausse C, Piattelli M, Pistilli R, Grandi G, Esposito M. Wide diameter immediate post-extractive implants vs delayed placement of normal-diameter implants in preserved sockets in the molar region: 1-year post-loading outcome of a randomised controlled trial. *Eur J Oral Implantol.* 2017;10:263–78.
- 19- McCullough JJ, Klokkevold PR. The effect of implant macro-thread design on implant stability in the early post-operative period: a randomized, controlled pilot study. *Clin Oral Implants Res.* 2017; 28:1218–26. <https://doi.org/10.1111/clr.12945>