

*Research Article***Efficacy of ultrasound guided erector spinae plane block on hemodynamic in patient undergoing abdominal surgery****Nagy S. Ali, Hassan M. Elshorbagy and Abeer A. M. Hassanien**

Department of Anesthesia and Intensive Care, Minia Faculty of Medicine, Egypt

Abstract:

Background: Thoracic epidural and paravertebral blocks are the most widely regional technique used for postoperative analgesia after abdominal surgery, but they are difficult to perform and carry a risk of serious complication. In this study, we tried to assess the efficacy of ultrasound ESPB on intraoperative and postoperative hemodynamics and patient satisfaction. **Patients and methods:** Sixty patients ASA I-III were scheduled for emergency laparotomy under general anesthesia. Patients were randomly allocated into two equal groups: ESPB group and control group. ESPB were administered after general anesthesia. Intraoperative and postoperative (HR and MAP) were recorded at preset time and compared. **Results:** Significantly decreased of intraoperative and postoperative hemodynamic in patients receiving ESPB with better impact on patient satisfaction. **Conclusion:** Bilateral ultrasound erector spinae plane block provides more hemodynamic stability and better patient satisfaction after emergency laparotomy.

Keywords: ESPB- Hemodynamic- Patient satisfaction**Introduction**

Good postoperative analgesia allows pain-free, early ambulation and decreasing the risks of long hospital stay, and other poor outcomes.¹ They are many regional anesthetic techniques for use in abdominal and thoracic procedures. One of these techniques is erector spinae plane block.

Forero et al., was the first who described ESPB to provide thoracic analgesia at the T5 transverse process. ESPB is easy to perform, need less training, and carry less risk than other techniques. ESPB provides extensive and potent analgesia due to extensive diffuse of local anesthetics to block the ventral and dorsal branches of the thoracic spinal nerves.²

The aim of the study was to assess the effect of ultrasound ESPB on intraoperative and postoperative hemodynamic and patient satisfaction in patients undergoing emergency laparotomy under general anesthesia.

Materials and methods

This prospective, double-blinded, randomized, controlled study was conducted at the period from August 2018 to July 2019. Sixty adults' patients ASA I-III, their ages ranged from 25-60 years undergoing to emergency laparotomy

under general anesthesia. Each patient assigned written informed consent before the block performance.

Patients refused, known allergy to the used drugs, with history of coagulopathy, major organ failure and obesity (BMI>40 kg/m²) were excluded from the study.

Exclusion criteria: patients were randomly allocated into two equal groups by a computerized randomization table created by a researcher who was not involved in the study: ESPB group, and control group. The patient and the staff providing the intra & postoperative care were blinded to the group assignment.

Anesthetic technique was standardized for all patients. Standard monitoring including pulse oximetry, noninvasive arterial pressure, and electrocardiography were applied prior to anesthetic induction. All patients were premedicated with intravenous midazolam 0.05 mg/kg and fentanyl 1 µg/kg. Induction was performed using propofol 1–2 mg/kg, and atracurium 0.5 mg/kg to facilitate tracheal intubation. Then, bilateral ultrasound guided ESP block was given to ESPB patients.

ESPB patients were placed in the lateral position. The anesthesiologist placed the ultra-

sound probe (SONOSITE M-TURBO, USA) in longitudinal orientation at the level of the T8 spinous process and then moved the probe 3 cm laterally from the midline. The ultrasound landmarks, which included the T8 transverse process and the overlying erector spinae muscle. Under aseptic conditions, a 90-mm 22-gauge block needle (GMS, Egypt) was inserted in-plane at an angle of 30–40° in cranial-to-caudal direction until the tip contacted the T8 transverse process. After hydro-dissection with 2–3 mL of isotonic saline solution confirmed the correct needle tip position, the anesthesiologist injected 20 mL of 0.25% bupivacaine deep to the erector spinae muscle. The same procedure was repeated with 20mL of 0.25% bupivacaine solution on the contralateral side.

1.2 minimum alveolar concentration isoflurane was used for anesthetic maintenance and atracurium 0.1 mg/kg. After completion of surgery, 0.05mg/kg neostigmine and 0.01mg/kg atropine were used to reverse residual neuromuscular blockade. The patients were extubated and transferred to the postoperative recovery room to receive postoperative care, analgesia in the form paracetamol 15 mg/kg/6 h IV (paracetamol 100ml 1%, Pharco B International) and monitoring of hemodynamics.

Outcome measures

Our primary endpoint to assess intraoperative and postoperative hemodynamics (Basal MAP and HR after induction, at time of infiltration,

at 5,10,15, 30, 45min, 1h, 1.5h, 2hrs and 2.5hrs after the block then heart rate and mean arterial pressure were recorded at 2,4,6,8, 10,12,18,24 hrs post-operatively). The secondary endpoint was evaluation of patient's satisfaction.

Statistical analysis

The analysis of the data was carried out using the IBM SPSS 20.0 statistical package software. Data were expressed as means \pm SD. Quantitative data are presented as mean \pm standard deviation, and qualitative data are presented as numbers and percentages. Quantitative data were analyzed with unpaired student t-tests; qualitative data were analyzed using chi-square and Z tests. $P < 0.05$ was considered statistically significant.

Results

Sixty-five patients scheduled for emergency laparotomy under general anesthesia. Five patients were excluded for refusal to participate. Patients were randomly allocated into two equal groups. No significant differences were noted for age, weight, ASA physical status, or surgery duration between groups.

Figure (1&2) clarified significant decline in intraoperative HR and mean arterial blood pressure in ESPB group in comparison with control group from 15 min till end of surgery.

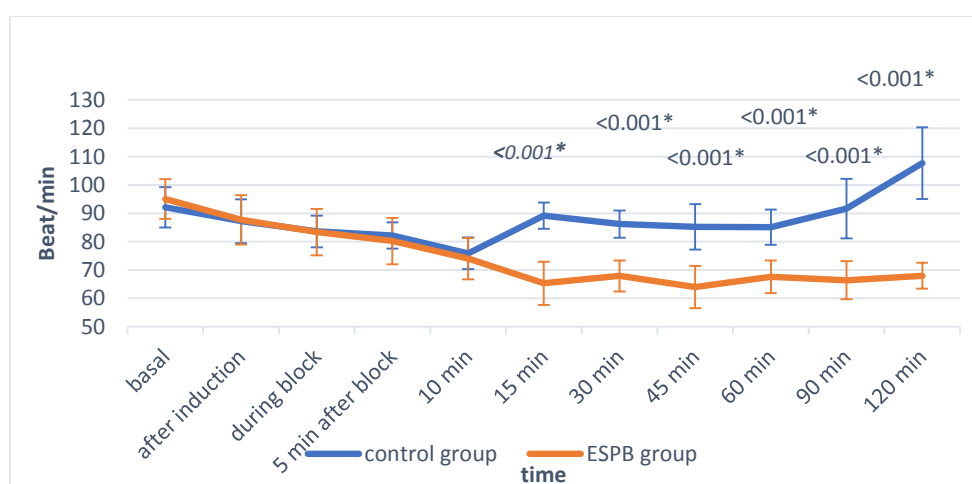


Figure 1: intraoperative mean HR.

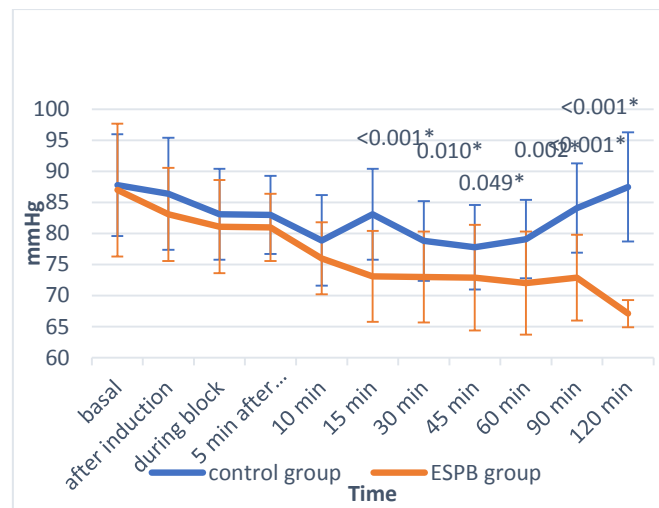


Figure2: intraoperative mean BP

Regarding postoperative HR, ESPB group significantly lesser than control group in the first 12 h, and in the first 18 h postoperatively regarding MAP, as illustrated in figure (3&4).

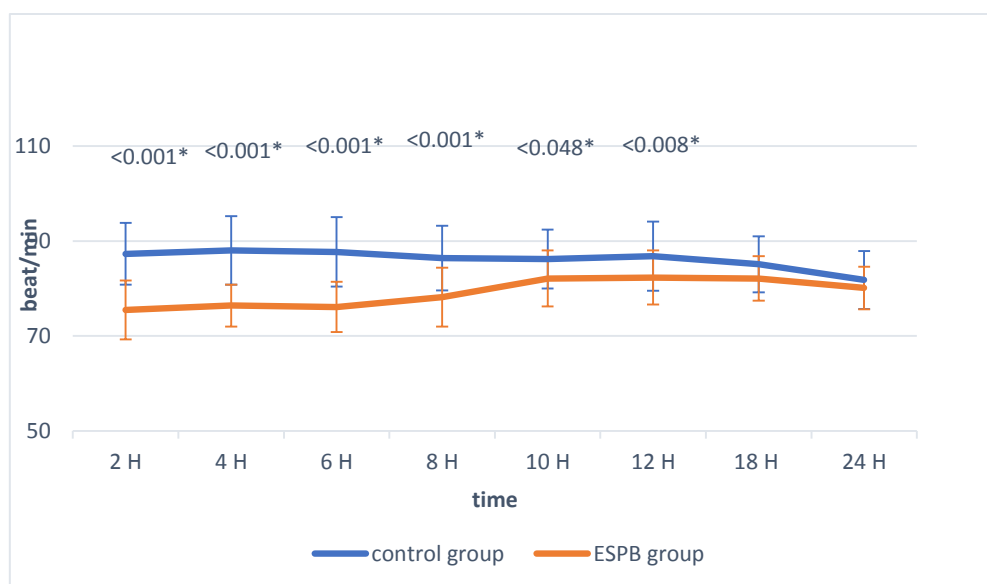


Figure 1:postoperative mean HR.

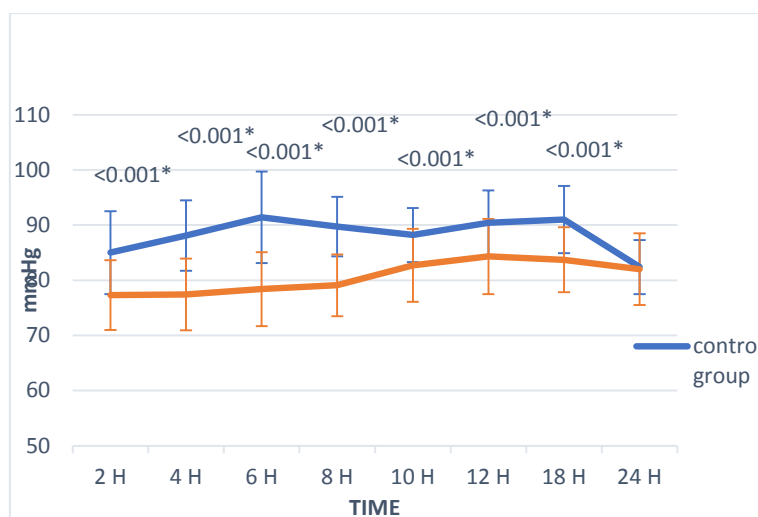


Figure 2: Postoperative mean BP.

As regard patient satisfaction, ESPB group show better compliance than control group as shown in **table (1)**.

Table(1) : Patient satisfaction. Data are illustrated as number and percentage.

	Control group (n=30) n (%)	ESPB group (n=30) n (%)	p value
Bad	0 (0)	0 (0)	<0.001*
Fair	24 (80 %)	0 (0%)	
Good	6 (20 %)	8 (26.7%)	
Excellent	0 (0)	22 (73.3%)	

Discussion

Abdominal wall blocks, such as rectus sheath block and the transversus abdominis plane block, have been used as alternatives to thoracic epidural analgesia and paravertebral blocks. however, abdominal wall blocks do not block visceral pain, and they require multiple injections and a large volume of local anesthetic to block a wide range of dermatomes.³

The ESPB is a relatively simple technique that uses easily distinguishable sonographic landmarks.⁴ In addition, once the tissues have been separated by a saline injection a catheter can be inserted into the plane. Unlike abdominal wall blocks, the ESPB can provide a wide range of sensory blockade of both the lower and upper abdomen. In addition, it is reported that the ESPB can supply both somatic and visceral analgesia, and it has a lesser risk of

Complications than paravertebral blocks or thoracic epidural analgesia.⁵

ESPB is a myofascial plane block employed as a simple and safe alternative analgesic technique to provide sensory block at multi-dermatomal levels across the posterior, lateral, and anterior chest wall. It can be used for acute post-surgical, post-traumatic, and chronic neuropathic thoracic pain. The extent of analgesia provided by ESP block depends upon the volume of drug, site of injection, approach of block, and pattern of spread within the myofascial plane.⁶

In the current study we found that, bilateral ultrasound erector spinae plane block provided better intraoperative and postoperative HR and BP stability with better impact on patient satisfaction in patient undergoing emergency laparotomy.

These results consistence with Li et al., 2020 who studied the efficacy of ultrasound guided erector spinae plane block for pain control in lumbar laminoplasty and they found that, patients who received ESP block had more stable hemodynamics and improved satisfaction than those using general anesthesia alone.⁷ On the other hand, Singh et al., 2019 used ultrasound guided erector spinae plane block for postoperative pain control in modified radical mastectomy and they found that There was no significant difference between ESPB group and control group with respect to HR, and mean arterial pressure during the perioperative period.⁸

Conclusion

The ultrasound guided ESP block can provide more hemodynamic control and stability during the perioperative period with better impact on patient satisfaction.

References

1. Azari L, Santoso JT, Osborne SE. Optimal pain management in total abdominal hysterectomy. *Obstet Gynecol Surv.* 2013; 68: 215–227.
2. Forero M, Adhikary SD, Lopez H, Tsui C, Chin KJ. The erector spinae plane block: a novel analgesic technique in thoracic neuropathic pain. *Reg Anesth Pain Med.* 2016;41: 621–627.
3. Chin KJ, McDonnell JG, Carvalho B, et al., Essentials of our current understanding: abdominal wall blocks. *Reg Anesth Pain Med* 2017; 42:133–83.
4. Kwon WJ, Bang SU, Sun WY. Erector spinae plane block for effective analgesia after total mastectomy with sentinel or axillary lymph node dissection: a report of three cases. *J Korean Med Sci* 2018; 33:e291.
5. Chin KJ, Malhas L, Perlas A. The erector spinae plane block provides visceral abdominal analgesia in bariatric surgery: a report of 3 cases. *Reg Anesth Pain Med* 2017; 42:372–6.
6. Kumar A, Sinha C, Kumar A, Kumari P. Modified erector spinae block for modified radical mastectomy: A novel technique. *Saudi Anaesth.* 2019;13(4):395-6.
7. Li J, Jin Y, Zhao S, Cai J, Blessing M, Sun Y, et al., Efficacy of Ultrasound-Guided Erector Spinae Plane Block for Perioperative Pain Control and Short-Term Outcomes in Lumbar Laminoplasty. *Med Rxiv.* 2020.
8. Singh S, Gunjan Kumar A. Ultrasound-guided erector spinae plane block for postoperative analgesia in modified radical mastectomy: A randomised control study. *Indian journal of anaesthesia.* 2019;63(3):200.